

Skin Cancer Detection

N. Durga Rao^{*}, Dr.G.Sudhavani[#]

^{*}Asst Professor, Vnitsw, Guntur, Andhrapradesh, India

[#]Professor R.V.R & J.C, Guntur, Andhrapradesh, India

ABSTRACT: In recent days, skin cancer is seen as one of the most Hazardous form of the Cancers found in Humans. Skin cancer is found in various types such as Melanoma, Basal and Squamous cell Carcinoma among which Melanoma is the most unpredictable. The detection of Melanoma cancer in early stage can be helpful to cure it. Computer vision can play important role in Medical Image Diagnosis and it has been proved by many existing systems. In this paper, we present a survey on different steps which are being to detect the Melanoma Skin Cancer using Image Processing tools. In every step, what are the different methods are be included in our paper.

Keywords: ABCD Rule, Melanoma, preprocessing, segmentation.

I. INTRODUCTION

Cancer begins when cells in the part of the body starts to grow out of control. A lesion means possibly abnormal change or difference in a tissue or structure such as the skin. Cancer is an uncontrolled growth of abnormal cells. The skin cancer is the uncontrolled growth of skin cells in the body. It develops when an unrepaired DNA damage to the skin cells and mostly caused by ultraviolet radiation of the sun or tanning beds, trigger mutations (genetic defects) which leads to the skin cells multiply rapidly and malignant tumors form. Some skin cancer can spread and cause damage in the near by tissue cells [1]. Also, in some cases, skin cancer can be on vital organs. Sun is the most common cause Of skin cancer. But it fully does not explain that skin cancer usually develop on the skin exposed to sunlight. Also it can be exposed to environmental threats, radiation analysis, and even inheritance could play a role. Although anyone can get skin cancer, the risk is greatest for people having bright skin or bright eyes, a wealth of large, irregular shaped moles, a genetic family history of skin cancer, an excessive sunlight or sunburn, lived in large or with year round sunshine, received radiation medication [2].

The sign of skin cancer often starts as the change of color in the skin. They are usually mixed color (pink, red, and brown). There are three types of skin cancer that occurred. They are- Basal cell cancer, squamous cell carcinoma and malignant melanoma tumor. The first two does not spread quickly, but the third one spreads quickly. Melanoma is much less common than basal cell and squamous cell skin cancer, but it is far more dangerous than the other two types. However, it is much more dangerous if it is not found early. It causes the majority (75%) of deaths related to

the skin cancer [3]. Worldwide, doctors investigate about 160,000 new cases of melanoma per year. It is mostly common in women than in men. In women, the most common part that the cancer occurs is the legs and in case of men the most common part is on the back. It is specifically common among Caucasians, and especially north Europeans those who lives in sunny climates. There are high rates of occurrences in Australia, North and South America, and North Europe, also with a disordered decrease in southern Italy and Sicily.

II. SKIN CANCER DETECTION

At first an image is acquired with a digital camera under consistent lighting. The proper interpretation of these dermoscopic images leads to increased clinical diagnostic accuracy. Most Automated Skin Lesion Diagnosis methods adopt the standard computer-aided diagnosis (CAD) pipeline which is illustrated in Fig: 1 and it consists of five general stages. After the image is acquired, it contains many artifacts such as hair and oil bubbles which could bias downstream processes are identified. Next, the lesion is segmented from the surrounding healthy skin. After segmentation, discriminative features are extracted from the lesion. Features which are usually extracted are border, color, entropy, compactness, radial variance of the mask, coarseness. Finally; by extracting these features the detection is done which finally shows the risk probability of the lesion which is present in the image.

2.1 Preprocessing

In this section, we describe the preprocessing steps that facilitate the border detection procedure namely, (1) Color space

transformation (2) Contrast enhancement (3) Artifact removal.

2.1.1 Color Space Transformation

Dermoscopy images are commonly acquired using a digital camera with a dermoscope attachment. Due to the computational simplicity and convenience of scalar (single channel) processing, the resulting RGB (red-green-blue) color image is often converted to a scalar image using one of the following methods:

- (i) Retaining only the blue channel (lesions are often more prominent in this channel).
- (ii) Applying the luminance transformation,
- (iii) Applying the Karhunen-Loève (KL) transformation [6] and retaining the channel with the highest variance.

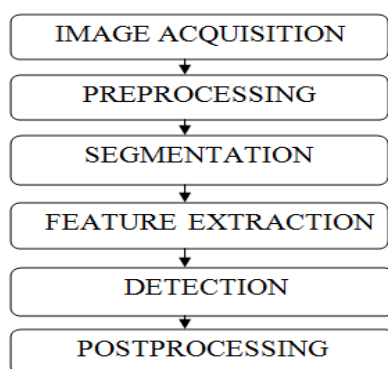


Fig: 1 Flowchart of skin cancer detection

2.1.2 Contrast Enhancement

One of the factors that complicate the detection of borders in dermoscopy images is insufficient contrast. Recently, Delgado et al. [4] proposed a contrast enhancement method based on Independent Histogram Pursuit (IHP). This algorithm linearly transforms the original RGB image to a decorrelated color space in which the lesion and the background skin are maximally separated. Border detection is then performed on these contrast enhanced images using a simple clustering algorithm.

2.1.3. Artifact Removal

Dermoscopy images often contain artifacts such as black frames, ink markings, rulers, air bubbles, as well as intrinsic coetaneous features that can affect border detection such as blood vessels, hairs, and skin lines. These artifacts and extraneous elements complicate the border detection procedure, which results in loss of accuracy as well as an increase in computational time. The most straightforward way to remove these artifacts is to smooth the image using a general purpose filter such as the Gaussian (GF), Median (MF), or Anisotropic Diffusion Filters

(ADF). Several issues should be considered while using these filters:

- Scalar vs. vector processing: These filters are originally formulated for scalar images. For vector images one can apply a scalar filter to each channel independently and then combine the results, a strategy referred to as marginal filtering. Although fast, this scheme introduces color artifacts in the output. An alternative solution is to use filters that treat the pixels as vectors [5].
- Mask size: The amount of smoothing is proportional to the mask size. However, excessively large masks result in the blurring of edges, which might reduce the border detection accuracy. Setting the mask size proportional to the image size seems to be a reasonable strategy [6,7].
- Computational time: For the GF and MF, algorithms that perform in constant time independent of the mask size have been developed [8,9]. As for the ADF, the computational time depends on the mask size and the number of iterations.

2.2 Segmentation

Image segmentation is the process of separating or grouping an image into different parts. These parts normally correspond to something that humans can easily separate and view as individual objects. Computers have no means of intelligently recognizing objects, and so many different methods have been developed in order to segment images

2.2.1. Methods for Image Segmentation

Image segmentation methods can be categorized as below (1) Region Based Methods (2) Edge Based Methods (3) Hybrid Techniques

2.3 Feature Extraction & Detection

Before extracting features from the skin lesion and classifying the lesion as malignant or benign, the location of the lesion border must be identified using a segmentation algorithm. Finding an accurate estimate of the lesion border is important because of the types of features used for classification. One common set of features is the ABCD scale: asymmetry, border irregularity, color variegation, and diameter.

To calculate the ABCD score, the 'Asymmetry, Border, Colors, and Dermoscopic structures' criteria are assessed semi quantitatively. Each of the criteria is then multiplied by a given weight factor to yield a Total Dermoscopy Score (TDS).

TDS values less than 4.75 indicate a benign melanocytic lesion, values between 4.8 and

5.45 indicate a suspicious lesion, and values of 5.45 or greater are highly suggestive of melanoma.

(1) **Asymmetry:** To assess asymmetry, the melanocytic lesion is bisected by two 90° axes that were positioned to produce the lowest possible asymmetry score. If both axes dermoscopically show asymmetric contours with regard to shape, colors and/or dermoscopic structures, the asymmetry score is 2. If there is asymmetry on one axis only, the score is 1. If asymmetry is absent with regard to both axes the score is 0.

(2) **Border:** The lesion is divided into eighths, and the pigment pattern is assessed. Within each one-eighth segment, a sharp, abrupt cut-off of pigment pattern at the periphery receives a score 1. In contrast, a gradual, indistinct cut-off within the segment receives a score of 0. Thus, the maximum border score is 8 and the minimum score is 0.

(3) **Color:** Six different colors are counted in determining the color score: white, red, light brown, dark brown, blue-gray, and black. For each color present, add +1 to the score. White should be counted only if the area is lighter than the adjacent skin. The maximum color score is 6 and the minimum score is 1.

(4) **Dermoscopic Structures:** Evaluation of dermoscopic structures focuses on 5 structural features: network, structure less (or homogeneous) areas, branched streaks, dots, and globules. The presence of any feature results in a score +1 Structure less (or homogenous) areas must be larger than 10% of the lesion to be considered present. Branched streaks and dots are counted only when more than two are clearly visible. The presence of a single globule is sufficient for the lesion to be considered positive for globules.

Formula for TDS: [(A score x 1.3) + (B score x 0.1) + (C score x 0.5) + (D score x 0.5)]

Table 1: The ABCD Score & Weight Factor

Criterion	Description	Score	Weight factor
Asymmetry	In 0, 1, or 2 axes; assess not only contour, but also colors and structures	0-2	X 1.3
Border	Abrupt ending of pigment pattern at the periphery in 0-8 segments	0-8	X 0.1
Color	Presence of up to 6 colors (white, red, light brown, dark brown, blue-gray, black)	1-6	X 0.5
Dermoscopic structures	Presence of network, structure less or homogeneous areas, branched streaks, dots, and globules	1-5	X 0.5

Table 2: TDS Score Interpretation

Total Dermoscopy Score (TDS)	Interpretation
<4.75	Benign melanocytic lesion
4.8-5.45	Suspicious lesion; close follow-up or excision recommended
>5.45	Lesion highly suggestive of melanoma
False-positive score (>5.45) sometimes observed in:	<ul style="list-style-type: none"> • Reed and Spitz nevus • Clark nevus with globular pattern • Congenital melanocytic nevus

2.4. Postprocessing

The result of the segmentation procedure is either a label image or a binary edge map. In order to obtain the lesion border, the segmentation output should be post processed. The precise sequence of post processing operations depends on the particular choice of the segmentation method. However, certain operations seem to be useful in general. These include:

- **Region merging:** Ideally, the segmentation procedure is expected to produce two regions: the lesion and the background skin. However, since these regions are rarely homogeneous, segmentation methods often partition them into multiple subregions. In order to obtain a single lesion object, subregions that are part of the lesion should first be identified and then merged.
- **Border smoothing:** Most segmentation methods produce regions with ragged borders. More natural borders can be obtained by a variety of operations including majority filtering [5], morphological filtering [6], and curve fitting.
- **Border expansion:** In several studies, it was observed that the computer-detected borders were mostly contained within the

dermatologist-determined borders. This is because the automated segmentation methods tend to find the sharpest pigment change, whereas the dermatologists choose the outmost detectable pigment. The discrepancy between the two borders can be reduced by expanding the computer detected border using morphological filtering [5], Euclidean distance transform [5], or iterative region growing [10].

III. CONCLUSION

In this study, we have discussed various methodologies for the melanoma diagnosis, combination of image processing and soft computing techniques yielded more accurate results to detect melanoma which will act as an aid for clinical diagnosis. The process of melanoma is carried out in various stages like preprocessing, segmentation, feature extraction, post processing which employ sophisticated techniques for getting accurate results.

References

- [1]. Yana Goncharova, Enas A. S. Attia, Khawla Souid, and Inna V. Vasilenko, "Dermoscopic Features of Facial Pigmented Skin Lesions," Hindawi Publishing Corporation, *Dermatology*, pp. 1-7, 2013
- [2]. Iris Zalaudek, M.D, Aimilios Lallas, Elvira Moscarella, Caterina Longo, H. Peter Soyer, Giuseppe Argenziano, "The dermatologist's applications traditional and new applications of dermoscopy," *Dermatol Pract Concept*, vol.3, no. 2, pp. 67-71, April 30, 2013.
- [3]. Cheng Lu, Muhammad Mahmood, Naresh Jha, and Mrinal Mandal, "Automated Segmentation of the Melanocytes in Skin Histopathological Images," *IEEE Journal Of Biomedical And Health Informatics*, Vol. 17, No. 2, Pp. 284-296, March 2013.
- [4]. Delgado D, Butakoff C, Ersboll BK, Stoecker WV. "Independent Histogram Pursuit for Segmentation of Skin Lesions" *IEEE Trans on Biomedical Engineering* 2008; 55(1):157-161.
- [5]. Celebi ME, Kingravi HA, Aslandogan YA. "Nonlinear Vector Filtering for Impulsive Noise Removal from Color Images". *Journal of Electronic Imaging* 2007; 16(3):033008. (21 pages)
- [6]. Schmid P. "Segmentation of Digitized Dermatoscopic Images by Two-Dimensional Color Clustering". *IEEE Trans on Medical Imaging* 1999; 18(2):164-171.
- [7]. Celebi ME, Kingravi HA, Iyatomi H, et al. "Border Detection in Dermoscopy Images Using Statistical Region Merging. *Skin Research and Technology*" 2008; 14(3):347-353. [Pub Med: 19159382]
- [8]. Geusebroek J-M, Smeulders AWM, van de Weijer J. "Fast Anisotropic Gauss Filtering". *IEEE Trans on Image Processing* 2003; 12(8):938-943.
- [9]. Perreault S, Hébert P." Median Filtering in Constant Time." *IEEE Trans on Image Processing* 2007; 16 (9):2389-2394.
- [10]. Iyatomi H, Oka H, Saito M, et al. "Quantitative Assessment of Tumor Extraction from Dermoscopy Images and Evaluation of Computer-based Extraction Methods for Automatic Melanoma Diagnostic System". *Melanoma Research* 2006; 16(2):183-190. [Pub Med: 16567974]