

Performance Analysis of Contourlet Features with SVM Classifier for the Characterization of Atheromatous Plaque in Intravascular Ultrasound Images

¹Selvathi D, ²Emimal N

¹Professor , Department of Electronics and Communication Engineering, Mepco Schlenk Engineering College, Sivakasi, Tamil Nadu, India.

²Assistant Professor, Department of Electronics and Communication Engineering, Er. Perumal Manimekalai College of Engineering, Hosur. Tamil Nadu, India.

ABSTRACT

Medical Image Processing has full-fledged in recent years and demands high accuracy since it deals with human creature. Artificial intelligent is one of the techniques used in this field which aims to reduce human error as much as possible. Hence, in this work, the local characterization of atheromatous plaque is proposed using the feature vector which includes the texture features extracted from the sub bands of third level contourlet transform. The extracted feature vectors are inputted to the SVM Classifier. The classifier differentiates each pixel in the IVUS image as Fibrotic, Lipidic and Calcified plaque tissues. The pixel based classification performance is assessed in terms of sensitivity, specificity and accuracy. The time taken to obtain the average accuracy of 95.92% is about 2 seconds under testing condition.

Keywords - Intravascular Ultrasound, Atheromatous Plaque, Contourlet Transform, SVM Classifier.

I. Introduction

CVDs are the number one cause of death globally, more people die annually from CVDs than from any other cause. By 2030, almost 25 million people will die from CVDs, mainly from heart disease and stroke [1]. Hardening of the arteries, also called atherosclerosis occurs when fat, cholesterol, and other substances build up in the walls of arteries and form hard structures called plaques. Other risk factors for hardening of the arteries are Diabetes, Family history of hardening of the arteries, High blood pressure and Smoking [2]. However, the manual identification of plaque is not straightforward since it is susceptible to prolonged and human error intrusion process.

Several approaches have been used for the characterization of atheromatous plaque. Some of them are semi-automatic and some of them are fully automatic. Semi-automatic methods require human intervention before it is given to the computer for processing. Amin Katouzian et al [3] described the realistic challenges in atherosclerotic plaque characterization. They explored the best reliable way to extract the most informative features and the classification algorithm which is most appropriate for this problem. Efthyvoulos C. Kyriacou et al [4] provides an overview of the several texture-feature extractions and classification methods and a

summary of emerging trends and future directions in 3-D imaging methods and plaque-motion analysis. L.S Athanasiou et al [5] proposed a plaque characterization technique using two geometrical features such as the first geometrical feature describes the relative position of the pixel from the outer border (media-adventitia) of the ROI and the second geometrical feature describes the relative position of a pixel from the outer border (media-adventitia) and from the inner border (lumen) of the ROI. An overall classification accuracy of 84.45% is reported and is not of high clinical value. Nikolaos N. Tsiaparas [6] et al proposed a comparative study on multiresolution approach for texture classification of atheromatous plaque from B-mode ultrasound images. They suggested that that wavelet-based texture analysis may be promising for characterizing atheromatous tissue. P. Loizou et al [7] analyzed the walls or layers of the artery for the identification of plaque by using AM-FM features. But this is limited to thin layer and due to the presence of speckle noise the visual and automatic analysis in ultrasound images gets hindered. Jose C. Seabra et al [8] proposed a method for plaque characterization in IVUS data based on a mixture of Rayleigh distributions. The coefficients and parameters of the mixture model are used as features

for describing fibrotic, lipidic, and calcified plaques. The Rayleigh distribution is widely used to describe homogeneous areas in ultrasound images. Since plaques may contain tissues with heterogeneous regions, distributions depending on multiple parameters are usually needed, such as Rice, K or Nakagami distributions. C. Takanori Koga et al [9] proposed fully automatic and semi-automatic plaque boundary extraction techniques for an intravascular ultrasound (IVUS) image using Fuzzy Inference-based method and it involves the future work of automatic adjustment of parameters along with the speed up of each calculation process. Monireh Sheikh Hosseini et al [10] reviewed the application of adaptive neuro-fuzzy inference system as classifier for different medical image classification during the past 16 years.

From the above analysis of existing method, the local characterization of Atheromatous plaque is proposed using the soft computing techniques such as pixel based classification using SVM through the GLCM features extracted from the sub bands of third level Contourlet transform.

II. PROPOSED METHODOLOGY

The basic steps involved in proposed methodology are shown in Fig. 1. The various stages include Contourlet Transform, Feature Extraction, Normalization Techniques and Classification using SVM Classifier.

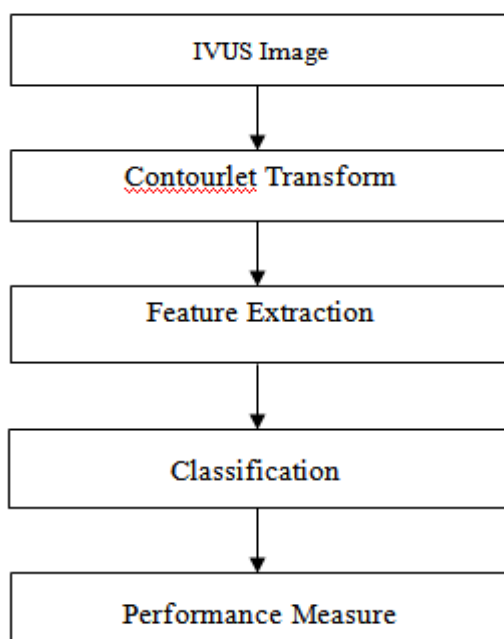


Fig. 1 Proposed Methodology

2.1 IVUS ARTERY IMAGES

Diagnostic imaging is an invaluable tool in

medicine today. There are different ways of acquiring artery images such as ultrasound, coronary angiography, cardiac CT and cardiovascular MRI. Among these ultrasound images are most commonly used because they are inexpensive, do not require ionizing radiations and are faster than other radiographic techniques. Also the penetrating nature of IVUS imaging technique helps for the visualization of the blood flow in the artery. Intravascular Ultrasound images used in this work are grayscale images and these are collected from the available resources [8]. The corresponding manually segmented ground truth images are also available.

2.2 CONTOURLET TRANSFORM

Contourlet transform is a double filter bank structure. It is implemented by the pyramidal directional filter bank (PDFB) which decomposes images into directional sub bands at multiple scales. In terms of structure the contourlet transform is a cascade of a Laplacian Pyramid and a directional filter bank. In essence, it first use a wavelet-like transform for edge detection, and then a local directional transform for contour segment detection. The Contourlet transform [11] provides a sparse representation for two-dimensional piecewise smooth signals that resemble images. Contourlet Transform produces 2^n sub bands for n levels of decomposition.

2.3 FEATURE EXTRACTION AND NORMALIZATION TECHNIQUES

It is the process of extracting significant information from an image. When the input data to an algorithm is too large to be processed and it is suspected to be notoriously redundant then the input data will be transformed into a reduced representation set of features (also named features vector). Transforming the input data into the set of features is called feature extraction. If the features extracted are carefully chosen it is expected that the features set will extract the relevant information from the input data in order to perform the desired task using this reduced representation instead of the full size input. In this work, the local characterization of atheromatous plaque is proposed using texture feature such as the Co- occurrence features [12] are extracted from the sub bands of third level Contourlet transform. The extracted features have to be normalized. The goal is to independently normalize each feature component to the [0,1] range. Hence, in this paper linear scaling to unit variance [13] has been used.

2.4 CLASSIFIER

Classifying data is a common task in machine learning. SVM (Support Vector Machine) is the simplest data classification method which finds an optimum hyper plane. The computational power of the learning machine is increased by using this classification scheme. In SVM classifier local minima are absent, there is no upper limit on the number of attributes. SVM Classifier can be used to model complex, real world problems like Text & image classification, Bioinformatics (Protein classification, Cancer classification) and handwritten character recognition. In this work, pixel based classification is used. Each pixel and its neighborhood are used for feature extraction. Overlapping matrices surrounding each pixel are taken and are used for extraction of texture features. After feature extraction, the extracted features are clubbed together into an array. The extracted features are given as input to the SVM classifier. In specific, it is the supervised method which requires data for training and then the trained features are used as the reference for automatically classifying the plaque tissue as fibrotic, lipidic, calcified or normal and it is used in this work.

2.5 PERFORMANCE MEASURE

The classification performance can be evaluated either qualitatively or quantitatively. The qualitative measurement shows only the visual results and it can only be described whereas the quantitative evaluation can provide precise results reflecting the exactness of evaluation. In this work, the quantitative evaluation of the different classification maps is carried out in the pixel level via the concept of confusion matrix which is a specific table layout that measures the performance of an algorithm, typically a supervised learning one.

2.5.1 CONFUSION MATRIX

In predictive analytics, a table of confusion (also called a confusion matrix), is a table with two rows and two columns that reports the number of false positives, false negatives, true positives, and true negatives. Each column of the matrix represents the instances in a predicted class, while each row represents the instances in an actual class. This allows more detailed analysis than mere proportion of correct guesses (accuracy). Accuracy is not a reliable metric for the real performance of a classifier, because it will yield misleading results if the data set is unbalanced (that is, when the number of samples in different classes vary greatly). The confusion matrix is shown in Table 1.

Table 1 Confusion Matrix

Condition (as determined by “Gold Standard”)	Test Outcome	
	Positive	Negative
Positive	True Positive	False Negative
Negative	False Positive	True Negative

2.5.2 SENSITIVITY

Sensitivity is the statistical measure which provides the proportion of actual positives which are correctly identified.

$$Sensitivity = \frac{TP}{TP + FN} \quad (1)$$

2.5.3 SPECIFICITY

Specificity is the statistical measure which provides the proportion of negatives which are correctly identified

$$Specificity = \frac{TN}{TN + FP} \quad (2)$$

2.5.4 ACCURACY

Accuracy reflects the overall correctness of the classifier

$$Accuracy(\%) = \frac{TP + TN}{TP + TN + FP + FN} * 100 \quad (3)$$

III. Results And Discussion

In this work, the IVUS image affected by three types of plaque content such as fibrotic, lipidic and calcified is used as the training image. The three types of plaque content are identified through the manually segmented image and hence the corresponding input image is used for training. The training image used and the corresponding manually segmented image are shown in the Fig 2. For segmentation based on pixel classification, training and testing data are required. The classifier is trained using the data extracted from the training image and to evaluate the performance of trained classifier, testing images are needed. The sample testing images used in this work are shown in the Fig 3.

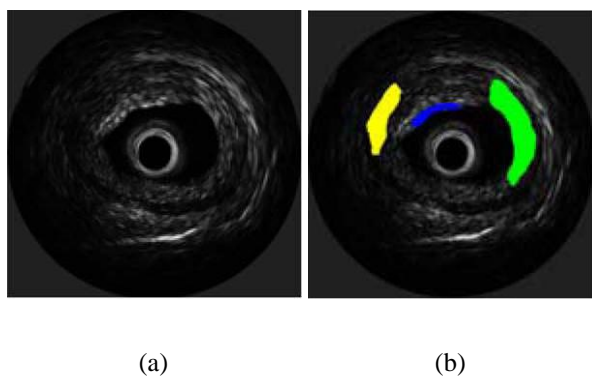


Fig. 2 (a) Training Image (b) Ground Truth

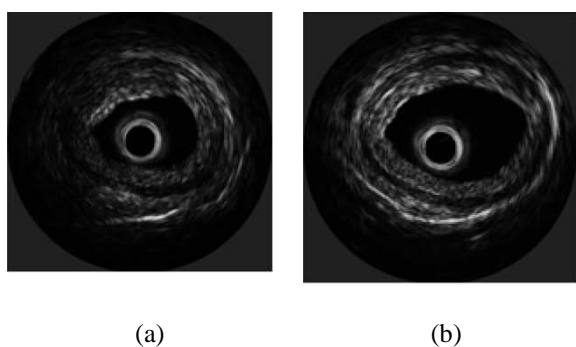


Fig. 3 Sample Images used in the Testing Phase

The normalized feature vectors such as the co-occurrence features extracted from the sub bands of third level Contourlet transform of the training image are used to train the SVM classifier. Using the trained classifier, the plaque affected regions in the untrained images are segmented and it is shown in the Figure 4.

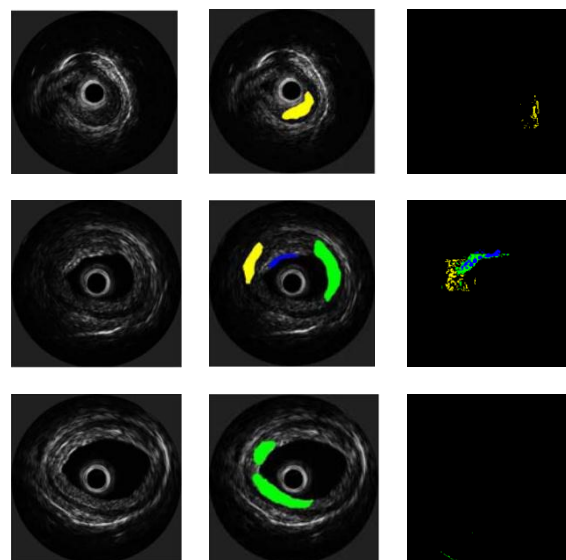
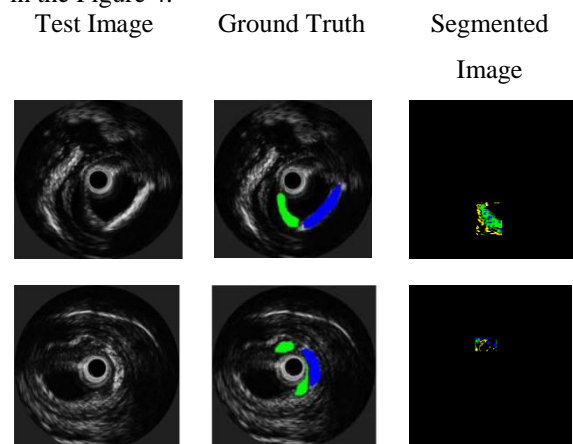


Fig. 4 Segmentation Results

The Confusion Matrix of five sample testing images for plaque characterization using the texture feature such as the co-occurrence features extracted from the sub bands of third level Contourlet transform are shown in the Table 2 and the corresponding quantitative measurements for individual and overall classes are shown in the Table 3 and in the Table 4 respectively.

Table 2(a) Confusion Matrix for Testing Image 1

		Predicted Class				
		F	L	C	N	T
Actual Class	F	524	139	115	633	1,411
	L	0	0	0	0	0
	C	8	0	0	2,252	2,260
	N	129	237	38	82,361	82,765
	T	661	376	153	85,246	86,436

Table 2(b) Confusion Matrix for Testing Image 2

		Predicted Class				
		F	L	C	N	T
Actual Class	F	11	54	11	1,470	1,546
	L	0	0	0	0	0
	C	0	0	0	1,512	1,512
	N	51	37	97	83,193	83,378
	T	62	91	108	86,175	86,436

Table 2(c) Confusion Matrix for Testing Image 3

	Predicted Class					
		F	L	C	N	T
Actual Class	F	0	0	0	0	0
	L	0	0	0	1,544	1,544
	C	0	0	0	0	0
	N	0	200	0	84,682	84,882
	T	0	200	0	86,236	86,436

Table 2(d) Confusion Matrix for Testing Image 4

	Predicted Class					
		F	L	C	N	T
Actual Class	F	0	0	0	2,935	2,935
	L	24	255	27	1,256	1,562
	C	159	0	222	93	474
	N	466	261	256	80,482	81,465
	T	649	516	505	84,766	86,436

Table 2(e) Confusion Matrix for Testing Image 5

	Predicted Class					
		F	L	C	N	T
Actual Class	F	0	0	0	3,609	3609
	L	0	0	0	0	0
	C	0	0	0	0	0
	N	32	0	0	82,795	82,827
	T	32	0	0	86,404	86,436

Table 3 Quantitative Analysis for Segmented Results

Images		Sensitivity	Specificity	Accuracy
1	Fibrotic	0.3714	0.9984	98.8153
	Lipidic	Undefined	0.9956	99.5650
	Calcified	0	0.9982	97.2083
	Normal	0.9951	0.2906	96.2122
2	Fibrotic	0.0071	0.9994	98.1651
	Lipidic	Undefined	0.9989	99.8947
	Calcified	0	0.9987	98.1258

	Normal	0.9978	0.0805	96.3438
3	Fibrotic	Undefined	1	100
	Lipidic	0	0.9976	97.9708
	Calcified	Undefined	1	100
	Normal	0.9976	0.1140	97.9754
4	Fibrotic	0	0.9922	95.8536
	Lipidic	0.1633	0.9969	98.1859
	Calcified	0.4684	0.9967	99.3810
	Normal	0.9879	0.2313	93.9486
5	Fibrotic	0	0.9996	95.7876
	Lipidic	Undefined	1	100
	Calcified	Undefined	1	100
	Normal	0.9996	0.0088	95.7892

Table 4 Overall Accuracy for Segmented Results

Images	Accuracy using Nakagami Features [14] (%)	Accuracy using proposed method (%)
1.	92.26	95.8929
2.	84.64	96.2620
3.	87.67	97.9719
4.	88.39	93.6647
5.	79.63	95.7888

Hence the segmentation performance is analyzed using confusion matrix which provides the standard measurements such as sensitivity, specificity and accuracy. The performance measure is quantified for various window sizes and it is evident that the accuracy for segmentation is better for window size two. From the table it is proved that images with single affected plaque are recognized more efficiently compared to the other images.

IV. Conclusion

Automatic characterization of Atheromatous plaque such as Fibrotic, Lipidic and

Calcified is quite challenging due to the lack of database. However, the proposed work using soft computing technique could significantly contribute to a study of plaque characterization, and consequently to an objective identification of plaque tissues with better accuracy. Further, the accuracy can be increased by choosing the appropriate training features and more number of samples. Moreover, a tool can be developed to automatically characterize the different plaque tissues such as Fibrotic, Calcified, and Lipidic in Ultrasound Images of a coronary artery. The developed system helps to win a battle against heart disease and stroke mortality.

References

- [1] <http://www.who.int/mediacentre/factsheets/fs317/en/index.html>
- [2] Libby P. The vascular biology of atherosclerosis. In: Bonow RO, Mann DL, Zipes DP, and Libby P, eds. *Braunwald's Heart Disease: A Textbook of Cardiovascular Medicine*. 9th ed. Philadelphia, Pa: Saunders Elsevier; 2011: chapter: 43.
- [3] Amin Katouzian, Shashidhar Sathyanarayana, Babak Baseri, Elisa E. Konofagou, and Stephane G. Carlier, "Challenges in Atherosclerotic Plaque Characterization with Intravascular Ultrasound (IVUS): From Data Collection to Classification," *IEEE Trans. On Information Technology in Biomedicine*, vol. 12, no. 3, pp. 315–327, May 2008.
- [4] Efthymoulos C. Kyriacou, Constantinos Pattichis, Marios Pattichis, Christos Loizou, Christodoulos Christodoulou, S. K. Kakkos, and Andrew Nicolaides, "A Review of Noninvasive Ultrasound Image Processing Methods in the Analysis of Carotid Plaque Morphology for the Assessment of Stroke Risk," *IEEE Trans. On Information Technology in Biomedicine*, vol. 14, no. 4, pp. 1027–1037, July 2010.
- [5] Athanasiou, L.S. Karvelis, P.S. Tsakanikas, V.D. Stefanou, K.A. Naka, K.K.; Michalis, L.K. Rigas, G.A. Fotiadis, D.I. Dept of Mater. Sci. & Eng., Univ. of Ioannina, Ioannina, Greece, "Atherosclerotic plaque characterization using geometrical features from virtual histology intravascular ultrasound images," *10th IEEE International Conference on Information Technology and Applications in Biomedicine(ITAB)*, pp:1-4 Nov. 2010
- [6] Nikolaos N. Tsiaparas, Spyretta Golemati, Ioannis Andreadis, John S. Stoitsis, Ioannis Valavanis, and Konstantina S. Nikita, "Comparison of Multiresolution Features for Texture Classification of Carotid Atherosclerosis From B-Mode Ultrasound," *IEEE Trans. on Information Technology in Biomedicine*, vol. 15, no. 1, pp. 130–137, January 2011.
- [7] C. P. Loizou, V. Murray, M. S. Pattichis and C. S. Pattichis, "Multiscale Amplitude-Modulation Frequency-Modulation (AM-FM) Texture Analysis of Ultrasound Images of the Intima and Media Layers of the Carotid Artery," *IEEE Trans. On Information Technology in Biomedicine*, vol. 15, no. 2, pp. 178–187, March 2011.
- [8] Jose C. Seabra, Francesco Ciompi, Oriol Pujol, Josepa Mauri, Petia Radeva, and Joao Sanches, "Rayleigh Mixture Model for Plaque Characterization in Intravascular Ultrasound," *IEEE Trans. On Biomedical Engineering*, vol. 58, no. 5, pp. 1314–1323, May 2011.
- [9] Takanori Koga, Eiji Uchino and Noriaki Suetake, "Automated boundary extraction and visualization system for coronary plaque in IVUS image by using fuzzy inference-based method," *IEEE International Conference on Fuzzy Systems*, pp. 1966-73, June 2011.
- [10] Monireh Sheikh Hosseini, Maryam Zekri, "A review of medical image classification using Adaptive Neuro-Fuzzy Inference System (ANFIS)," *Journal of Medical Signals and Sensors* vol:2, no.1 pp. 51-62, January 2012.
- [11] Minh N. Do, and Martin Vetterli, "The contourlet transform: an efficient directional multiresolution image representation," *IEEE trans. on Image Processing*, vol. 14, no. 12, pp. 2091 - 2106, December 2005.
- [12] Parekh. R, "Using Texture Analysis for Medical Diagnosis," *IEEE Multi-Media*, vol.19, no.2, pp.28-37, February 2012.
- [13] Selim Aksoy, Robert M. Haralick, "Feature normalization and likelihood-based similarity measures for image retrieval," *Pattern Recognition Letters*, vol. 22, no.5, pp.563-582, April 2001.
- [14] Selvathi D, Emimal N, "Statistical Modeling for the characterization of Atheromatous Plaque in Intravascular Ultrasound Images," *IEEE International Conference on Devices, Circuits and Systems (ICDCS)*, Mar. 2012.