

How to plan 3D Navigated Coronary Angiogram - Technique

Mr Eldhose George^{*}, Miss Aatiqa Imtiaz^{**}, Mr. Muhibullah^{***}, Dr. Sohail Iqbal^{****}

^{*}Senior Radiographer, Alliance Cardiac MRI Centre, Wythenshawe Hospital, Manchester, M23 9LT, UK

^{**}University of Lahore, Lahore, Pakistan

^{***}Nishter Medical College, Multan, Pakistan

^{****}Department of Cardiac Imaging, North West Heart Centre, Wythenshawe Hospital, MFT NHS Foundation Trust, M23 9LT, UK.

ABSTRACT

Coronary artery anatomy including their number, origin and course are important subject matter of cardiac imaging and is usually studied by cardiac CT. However, cardiac magnetic resonance imaging is playing an increasing role in this aspect because of its radiation free nature and superior soft issue resolution. 3D navigated coronary angiography is non contrast technique which incorporates electrocardiography (ECG) and respiratory motion triggering to acquire sharp images in free breathing mode. Here we aim to present step by step guide to explain the technical issues relating to this technique.

Keywords - Aberrant Coronary Arteries, Coronary Arteries course, Coronary Arteries origin, MRA, 3D Navigated Coronary Angiography

Date of Submission: 12-03-2021

Date of Acceptance: 27-03-2021

I. INTRODUCTION

3D navigated coronary angiogram is a radiation free technique to study the origin and course of the coronary arteries [1]. Its acquisition details will be discussed in this short article. It can be performed as part of full cardiac MRI study including viability and perfusion or as a stand-alone technique where coronary angiogram is planned outrightly after localizers, Half-Fourier Acquisition Single-shot Turbo spin Echo imaging (HASTE) and three long axis Steady-state free precession (SSFP) cine images. Patient should breathe normally throughout [2].

II. TECHNIQUE

- ✚ Acquire a new CH4 by changing “calculated phases” to 50 – on physio page.
- ✚ Determine window when the coronary sinus has the least movement by scroll through the diastole (Fig 1).
- ✚ If the patient’s heart beats above 75 to 80 beats per minute, systole is the optimum phase to find the right and left coronary arteries.
- ✚ Note the TT value (bottom left corner of the image) at the beginning and end of this window.
- ✚ Deduct the start and end TT values to determine the window duration in milliseconds.
- ✚ In “Other Sequences,” choose FB COR LOC.
- ✚ Copy to the LVOT view and run (Fig 2).
- ✚ In “Other Sequences,” choose 3D Whole Heart.

- ✚ Put the free breathing image in the middle (perp on this one), field of view covering the aortic sinuses.
- ✚ Put the HASTE in the far right and the LVOT or CH3 view in the far left.
- ✚ Using the HASTE find the diaphragm, put the centre circle of the navigator lines on the dome of diaphragm, check in the FB view (Fig 3).
- ✚ In the Physio page, capture cycle.
- ✚ Hover over trigger delay, this will display window duration & window start times (in milliseconds).
- ✚ Amend trigger delay to achieve the required window start time – this should be after the start calculated from CH4 TT.
- ✚ Amend segments to achieve the required window duration – this should be within the duration calculated from CH4 TT start and end times.
- ✚ DO NOT CAPTURE CYCLE AGAIN AFTER YOU HAVE SET UP YOUR WINDOW!!!!
- ✚ In the Physio page, choose PACE, Scout Mode ON & apply.
- ✚ Watch the Scout to determine the optimum search position.
- ✚ Drag down 3D whole heart.
- ✚ In the Physio page, choose PACE turn off Scout Mode.
- ✚ Type in Search Position Red – from the scout.
- ✚ Apply – acceptance rate should be >30%.

Some measurements as on Siemen's 3T scanner:
 If TT at coronary start window is 620 and end window is 820 duration for data acquisition would be (820-620) 200.

At data window start select the start window value 620 (Fig 4)

If you calculate your data window duration + data window start you will get your coronary end window for example 190+620=810

- Play with segments if you want to increase your data window duration
- If you want to increase the data window start, adjust the trigger delay

Tr - 314.53

Segments - 35

Accept window 2.5 - if you increase the accept window 2.5 to 3 it will acquire data quicker on the expense of the image quality

Search position - when it is run in scout mode you will be able to see the search position value

III. FIGURES

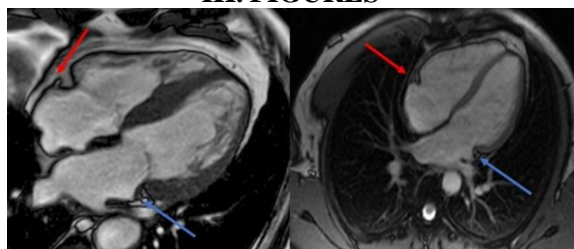


Fig 1) Window selection for duration of stationary phase of right (orange arrow) and left (blue arrow) coronary arteries

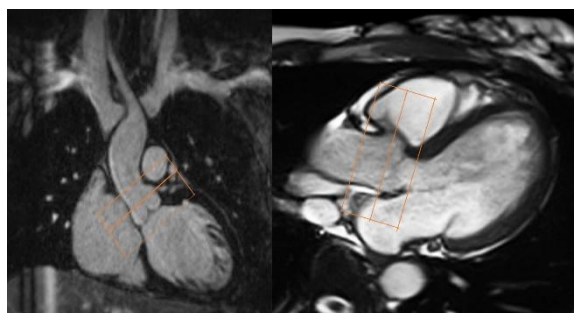


Fig 2) Selection of aortic root on left ventricular outflow tract (LVOT) and three chamber (3C) views

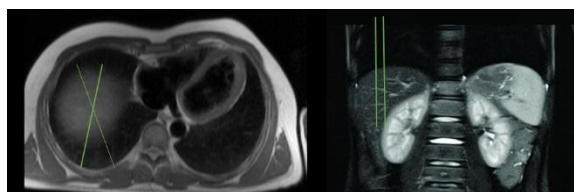


Fig 3) Application of breathing navigator over the diaphragm by using axial and coronal HASTE and TRUEFISP or localizer images

1st signal mode ECG trigger

Average cycle 575 +/-250

Capture cycle

Acquisition window 908

Trigger pulse 1

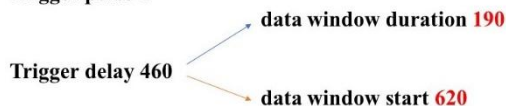


Fig 4) Acquisition criteria on Siemen's 3T scanner

IV. CONCLUSION

3D navigated coronary angiogram is non contrast radiation free technique to study the origin and course of coronary arteries and to investigate any aberrancy which might compromise coronary blood flow. The purpose of this article is to simply elaborate the step by step technique to facilitate young radiographers and image interpreting physicians.

REFERENCES

- [1]. Velasco Forte, M.N., Valverde, I., Prabhu, N. et al. Visualization of coronary arteries in paediatric patients using whole-heart coronary magnetic resonance angiography: comparison of image-navigation and the standard approach for respiratory motion compensation. J Cardiovasc Magn Reson 2019; 21: 13. <https://doi.org/10.1186/s12968-019-0525-8>
- [2]. Stroud, R.E., Piccini, D., Schoepf, U. et al. Correcting versus resolving respiratory motion in free-breathing whole-heart MRA: a comparison in patients with thoracic aortic disease. Eur Radiol Exp 2019; 3: 29. <https://doi.org/10.1186/s41747-019-0107-4>