

## Detection of Diabetic Retinopathy using deep Convolutional Neural Network

<sup>1</sup> Yenni Manaswini<sup>2</sup>Dr.Jhansi Rani Singothu

Dept of Information Technology and Computer Applications,  
Assistant Proffesor,<sup>1</sup>Department of Computer Science and Systems Engineering  
Andhra University College Of Engineering(Autonomous)  
Andhra University, Visakhapatnam, Andhra Pradesh, India.

### ABSTRACT:

A recent development in the state-of-art technology machine learning plays a vital role in the image processing applications such as biomedical, satellite image processing, Artificial Intelligence such as object identification and recognition and so on. Severity of the diabetic retinopathy disease is based on a presence of micro aneurysms, exudates, neovascularization, Haemorrhages. The purpose of this project is to design an automated and efficient solution that could detect the symptoms of DR from a retinal image within seconds and simplify the process of reviewing and examination of images. Diabetic Retinopathy (DR) is a complication of diabetes that is caused by changes in the blood vessel of the retina and it is one of the leading causes of blindness in the developed world. Currently, detecting DR symptoms is a manual and time-consuming process. In our approach, we trained a deep Convolutional Neural Network model on a large dataset consisting around 35,000 images and used dropout layer techniques to achieve higher accuracy. Amongst other supervised algorithms involved, proposed solution is to find a better and optimized way to classifying the fundus image with little pre-processing techniques. Our proposed architecture deployed with dropout layer techniques yields around 94-96 percent accuracy.

**Keywords:** Diabetic Retinopathy, Convolutional Neural Network, Relu,Drop-Out, Fundus Images, Neural Network, Macula, Optic Disc Feature learning, deep learning, Convolutional Neural Networks

Date of Submission: 06-11-2020

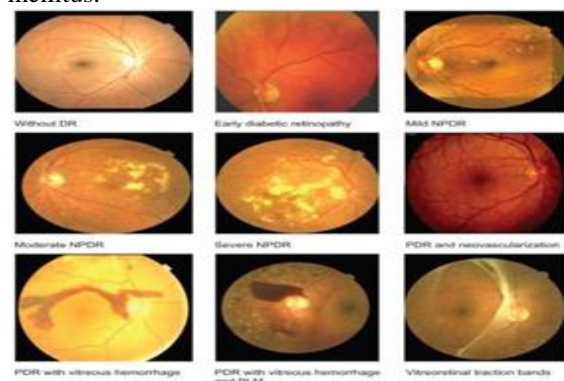
Date of Acceptance: 19-11-2020

### I. INTRODUCTION

Diabetic retinopathy also known as diabetic eye disease, is when damage occurs to the retina due to diabetes. It's a systemic disease, which affects up to 80 percent of all patients who have had diabetes for 20 years or more. Despite these intimidating statistics, research indicates that at least 90% of these new cases could be reduced if there were proper and vigilant treatment and monitoring of the eyes. The longer a person has diabetes, the higher his or her chances of developing diabetic retinopathy.

According to the International Diabetes Federation, the number of adults with the diabetes in the world is estimated to be 366 million in 2011 and by 2030 this would have risen to 552 million. The number of people with type 2 diabetes is increasing in every country 80% of people with diabetes live in low-and middle-income countries. India stands first with 195%(18 million in 1995 to 54 million in 2025). Previously, diabetes mellitus(DM) was considered to be present, largely, among the urban

population in India. Recent studies clearly show an increasing prevalence in rural areas as well. Indian studies show a 3-fold increase in the presence of diabetes among the rural population over the last decade or so (2.2% in 1989 to 6.3% in 2003).In India, Study shows the estimated prevalence of type 2 diabetes mellitus and diabetic retinopathy in a rural population of south India are nearly 1 of 10 individuals in rural south India, above the age of 40 years, showed the evidence of type 2 diabetes mellitus.



**Fig 1. Diabetic retinopathy stages**

There are five major level of clinical DR severity. Many patients have no clinically observable DR early after DM diagnosis, yet there are known structural and physiologic changes in the retina including slowing of retinal blood flow, increased leukocyte adhesion, thickening of basement membranes, and loss of retinal pericytes. The earliest clinically apparent stage of DR is mild non-proliferative diabetic retinopathy (NPDR) characterized by the development of micro aneurysms. The disease can progress to moderate NPDR where additional DR lesions develop, including venous caliber changes and intraregional microvascular abnormalities. The severity and extent of these lesions is increased in severe NPDR, and retinal blood supply becomes increasingly compromised. As a consequence, the non-perfused areas of the retina send signals stimulating new blood vessel growth, leading to proliferative diabetic retinopathy (PDR). The new blood vessels are abnormal, friable, and can bleed easily often causing severe visual loss. Diabetic macular edema (DME) occurs when there is swelling of the retina due to leaking of fluid from blood vessels within the macula, and can occur during any stage of DR.

Diabetic retinopathy is one of the common complications of diabetes. It is a severe and widely spread eye disease. It damages the small blood vessels in the retina resulting in loss of vision. The risk of the disease increases with age and therefore, middle aged and older diabetics are prone to Diabetic Retinopathy. The progression from no retinopathy to PDR can take 2 decades or more, and this slow rate enables DR to be identified and treated at an early stage. Development and progression of DR are related to duration and control of diabetes. DR in its early form is often asymptomatic but amenable to treatment. Diabetic retinopathy may progress through four stages:

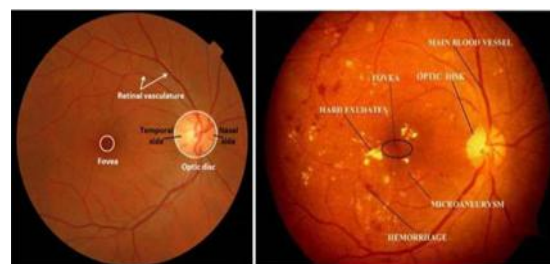
1. Mild nonproliferative retinopathy - Small areas of balloon-like swelling in the retina's tiny blood vessels, called micro aneurysms, occur at this earliest stage of the disease. These micro aneurysms may leak fluid into the retina.
2. Moderate non-proliferative retinopathy - As the disease progresses, blood vessels that nourish the retina may swell and distort. They may also lose their ability to transport blood. Both conditions cause characteristic changes to the appearance of the retina and may contribute to DME.
3. Severe non-proliferative retinopathy - Many more blood vessels are blocked, depriving

blood supply to areas of the retina. These areas secrete growth factors that signal the retina to grow new blood vessels.

4. Proliferative diabetic retinopathy (PDR) - At this advanced stage, growth factors secreted by the retina trigger the proliferation of new blood vessels, which grow along the inside surface of the retina and into the vitreous gel, the fluid that fills the eye. The new blood vessels are fragile, which makes them more likely to leak and bleed. Accompanying scar tissue can contract and cause retinal detachment—the pulling away of the retina from underlying tissue, like wallpaper peeling away from a wall. Retinal detachment can lead to permanent vision loss.

**Problems in Diabetic Retinopathy Detection**

Diabetic Retinopathy is the leading cause of blindness in the working-age population of the developed world. It is estimated to affect over 93 million people. The US Center for Disease Control and Prevention estimates that 29.1 million people in the US have diabetes and the World Health Organization estimates that 347 million people have the disease worldwide. Diabetic Retinopathy (DR) is an eye disease associated with long-standing diabetes. Progression to vision impairment can be slowed or averted if DR is detected in time, however, this can be difficult as the disease often shows few symptoms until it is too late to provide effective treatment. Currently, detecting DR is a time-consuming and manual process that requires a trained clinician to examine and evaluate digital color fundus photographs of the retina. By the time human readers submit their reviews, often a day or two later, the delayed results lead to lost follow up, miscommunication, and delayed treatment. Unfortunately, there is no effective known cure for diabetic retinopathy and the present treatments available are just management strategies at best. So it's very important to detect the disease in its early stages.



**Fig. 2 FUNDUS image features**

Optic Disc: OD is the region of the posterior pole where the vasculature and retinal

nerve axons enter and leave the eye. The OD in a healthy retinal image usually appears as a bright yellowish and elliptical object marked by surface vessels. The presence of pathologic changes occurring at the site. Of the OD, such as neovascularization from DR or changes to the physiologic c p due to glaucoma, can also affect its appearance dramatically.

**Macula:** The macula or macula lutea is an oval-shaped pigmented area near the center of the retina of the human eye. It has a diameter of around 5.5 mm (0.22 in). The fovea is located near the center of the macula. It is a small pit that contains the largest concentration of cone cells. The macula is thus responsible for the central, high-resolution, color vision that is possible in good light; and this kind of vision is impaired if the macula is damaged, for example in macular degeneration.

**Exudates:** These yellow flecks are called exudates. They are the lipid residues of serious leakage from damaged capillaries. The commonest cause is diabetes.

**Microaneurysms:** A microaneurysm is a tiny aneurysm, or swelling, in the side of a blood vessel. In people with diabetes, microaneurysms are sometimes found in the retina of the eye. These miniature aneurysms can rupture and leak blood.

**Hemorrhages:** Retinal hemorrhage is bleeding from the blood vessels in the retina, inside your eye. Your retina is the thin layer that lines the back of your eye. Medical conditions, such as diabetes, high blood pressure, anemia, or leukemia. Eye problems, such as macular degeneration, or a bulging of the blood vessels in the retina. You may have no symptoms. You may have a sudden or gradual loss of vision, ranging from mild to severe. You may have blind spots.

Types of eye diseases (With their corresponding FUNDUS image)

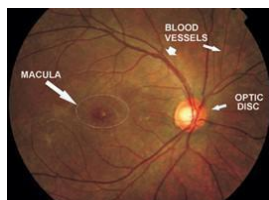

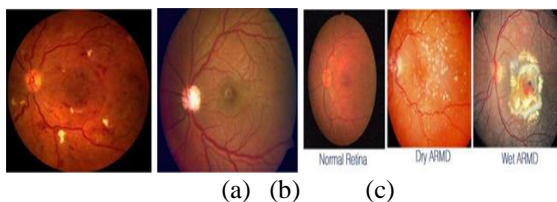


Fig. 3 - A Healthy Fundus



(d)(e)(f)  
**Fig. 4 Retinal image of an eye having (a) Diabetic Retinopathy (b) Glaucoma (c) AMD (age-related macular degeneration); Image saw by people having disease (d) Diabetic Retinopathy (e) Glaucoma (f) AMD**

## II. RELATED WORKS

A supervised classification is based on classifying the test image dataset from the training data with a labeled classes. In general, classification is done by extracting the features from the images followed by identifying the categorized classes based on the trained data with labeled classes. In Classification, the extracted features listed out the severity of the diabetic retinopathy diseases. There are five categories of diabetic retinopathy classification from non-proliferative diabetic retinopathy to proliferative diabetic retinopathy are classified based on extracted feature values.

Some of the popular methodologies well utilized to do feature extraction and classification of diabetic retinopathy analysis are :

S.Wang, et al[1], using convolutional neural network performs as a trainable hierarchical feature extractor and Random Forest(RF) as a trainable classifier. It has 6 stacked layers of convolution and followed by sub sampling layers for feature extraction. Random Forest algorithm is utilized to for classifier ensemble method and introduced in the retinal blood vessel segmentation. This architecture is used in the DRIVE, STARE databases and achieved around 0.98 and 0.97.

MrinalHaloi et al[2], a new deep learning based computer-aided system for microaneurysm detection. Comparing other deep neural network, it required less preprocessing, vessel extraction and more deep layers for training and testing the fundus image dataset. It consists of five layers which includes convolutional, max pooling and Softmax layer with additional dropout training for improving an accuracy. It achieved low false positive rate. And the performance measured as 0.96 accuracy with 0.96 specificity and 0.97 sensitivity.

M.Melinscak et al[3], an automatic segmentation of blood vessels in fundus images. It contain a deep max-pooling convolutional neural networks to segment blood vessels. It is deployed 10-layer architecture for achieving a maximum accuracy but worked with small image patches. It contain a preprocessing for resizing and reshaping



the fundus images. Also, this method achieved an accuracy around 0.94.

Gardner et al[4], a pioneer method of diabetic retinopathy screening tool using artificial neural network with preprocessing techniques. This method learned features from the sub-images. It heavily relied on back propagation neural network. It contains set of diabetic features in fundus images and compare against the ophthalmologist screening set of fundus images. Its a wholistic approach of recognition of vessels, exudates and haemorrhages were 91.7%, 93.1% and 73.8%.

Sohini Roychowdhury et al[5] proposed a novel two stage hierarchical classification algorithm for automatic detection and classification. For automated detection, novel two-step hierarchical binary classification is used. For classification of lesions from non-lesions proposed GMM, SVM, KNN and ADABOOST methods are used. They take 30 top features like are, variance of Ired channel, Igreen channel, I sat of object, major and minor axis length, Mean pixels for Igreen, Ired and intensity, solidity etc. The DREAM system 100 percent sensitivity, .5316 specificity achieved. Also, carried out average computation time for DR severity per image from 59.54 to 3.46s. overall feature reduction effects the average computation time.

Jayakumar Lachure et al[6], retinal micro-aneurysms, hemorrhages, exudates, and cotton wool spots are the abnormality find out in the fundus images. Detection of red and bright lesions in digital fundus photographs. This SVM classifier optimized to 100 percent and 90 percent sensitivity.

R. Priya, P. Aruna et al[7], to diagnostic retinopathy used two models like Probabilistic Neural network (PNN) and Support Vector Machines. The input color retinal images are pre-processed using grayscale conversion, adaptive histogram equalization, discrete wavelet transform, matched filter and fuzzy C-means segmentation. The classification of pre-processed images features were extracted. It achieved an accuracy of 89.6 percent and SVM of around 97.608 percent.

Giraddi et al[8], detection of the exudates in the color variability and contrast retinal images. Comparative analysis made for SVM and KNN classifier for earliest detection. As a result, KNN outperforms SVM with color as well as texture features.

Srivastava et al[9], a key idea of randomly drop units along with their connections during the training. His work significantly reduces the over fitting and gives improvements over other regularization techniques.

### III. DIABETIC RETINOPATHY DETECTION SYSTEM

Our detection approach entails training a Convolutional Neural Network (CNN) to classify the level of DR in images. So, for training data, we were provided with approximately 35,126 labeled high-resolution images from Kaggle (online platform for data science competitions) taken under a variety of imaging conditions.

A clinician has rated the presence of diabetic retinopathy in each image on a scale of 0 to 4, according to the following scale:

- 0 - No DR
- 1 - Mild
- 2 - Moderate
- 3 - Severe
- 4 - Proliferative DR

Images were labeled with a subject id as well as either left or right (e.g. 1\_left.jpeg is the left eye of patient id 1). We then further augmented our training data to twice its original size. Then, we divided our training data itself into 20% validation data to fine tune our model. In all, there are roughly 61,000 training images and 14,000 validation images with 5 classification labels.

Preprocessing: Since the original images are fairly large (say, 3000x2000 pixels on average) and most of them contained a fairly large significant black border. We started removing most of these black borders but before that, as we required square matrix images as the input of our network, the images were first resized to say 3000 x 3000 (in the case of 3000 x 2000) by adding extra black borders and then resizing these images to 448 x 448. As if this does not take care correctly, we may have distorted FUNDUS images which may lose its original circular shape.

A primary step involved in the preprocessing is resizing the images into dimensions of 448x448.

Before feeding into the architecture for classification.

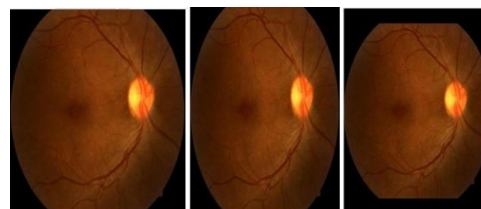


Fig. 5 (a) Image without preprocessing (say, 2000x3000) , (b) Image preprocessed without adding black borders(448x448), (c) Image preprocessed with adding black borders(448x448)

#### IV. PROPOSED METHODOLOGY

In recent years most of the image processing researchers indulged in the development of machine learning especially deep learning approaches in the field of Hand-written digit recognition such as MNIST dataset, image classification by IMAGENET. Our proposed methodology strongly emerged based on these key aspects of diseases severity classification from the fundus images.

In general, especially classification of diseases with the proposed architecture a DCNN[add citation] following these basic steps to achieve maximum accuracy from the images dataset are

- i) Data Augmentation
- ii) Pre-processing
- iii) Initialization of Networks
- iv) training
- v) Activation function selections
- vi) Regularizations
- vii) Ensemble the multiple methods.

In our proposed diabetic retinopathy classification model in Fig.3.1, an architecture are condensed and its building blocks are :

- a) Data augmentation
- b) Pre-processing
- c) Deep Convolutional Neural Network Classification

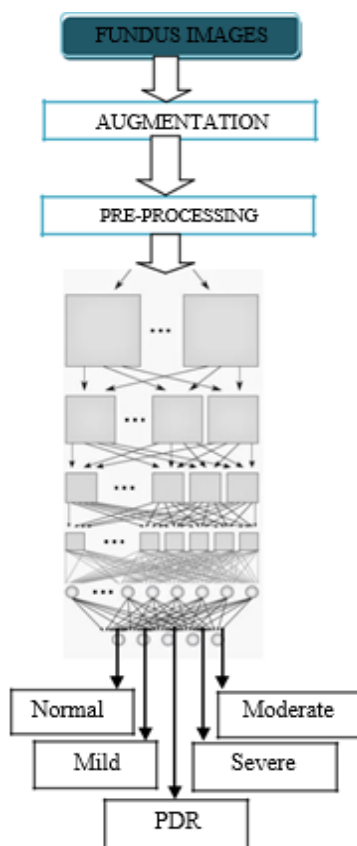


Fig 3.1 Block diagram of proposed model

#### A. DATA AUGMENTATION

The fundus images are obtained from the different datasets are taken under different camera with varying field of view, non-clarity, blurring, contrast and sizes of images different. In data augmentation, contrast adjustment, flipping images, brightness adjustments are made.

#### B. PREPROCESSING

For Deep convolutional neural network worked on spatial data of the fundus images. A primary steps involved in the preprocessing is resizing the images. Before feeding into the architecture for classification, convert the images in to gray scale. And then, convert in to the L model. It is a monochrome images which is used to highlights the microaneurysms, and vessels in the fundus images. And flatten the images in single dimensional for processing further.

#### C. CNN CLASSIFICATION

In Image recognition, a Convolutional Neural Network(CNN) is a type of feed-forward artificial neural network in which the connectivity pattern between its neurons is inspired by the organization of animal visual cortex, whose individual neurons are arranged in such a way that respond to overlapping regions tiling the visual field.

In deep learning, [10][11] the convolutional neural network uses a complex architecture composed of stacked layers in which is particularly well-adapted to classify the images. For multi-class classification, this architecture robust and sensitive to each feature present in the images.

Common layers deployed in making Deep Convolutional Neural Network architecture(DCNN) are shown in Fig. 3.2

- i) Convolutional Layer
- ii) Pooling Layer
- iii) ReLU Layer
- iv) Dropout layer
- v) Fully connected Layer
- vi) Classification Layer

#### i) CONVOLUTIONAL LAYER :

This is the first and foremost layer laid after the input image which want to be classified. The backbone of the convolutional neural network are: local receptive fields, shared weights. These are making deep convolutional neural network for image recognition.

#### Local receptive field:

During image recognition, convolutional neural network consists of multiple layers of small

neuron collections which look at small portions of the input image.

**Shared weights and bias:**

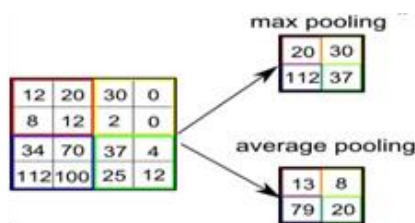
Each feature map of the convolutional neural network shared the same weights and bias values. This shared values will represent the same feature all over the image. Depends on the application, the feature map generation is varied.

The convolutional layer consists of kernel or set of filters(local receptive field) . Each filter is convolved against the input image and extract the features by forming a new layer or activation map. Each activation map contain or represent some significant characteristic or features of the input image.

In convolutional layer ,NxN input neuron layer is convoluted with mxm filter. Then, the convolutional layer output will be of size (N-m+1)x(N-m+1).It applied non-linearity through neural activation function.

**ii) POOLING LAYER**

This is one of the most significant layer which helps the network from avoiding over-fitting by reduce the parameters and computation in the network.It works as a form of non-linear down sampling. Pooling partition the activation maps into set of rectangles and collect the maximum value in the sub region. It's merely a downsize the pixels with features. For instance, if NxN input layer, that will give output layer of N/K x N/K layer.



This activation function induces the sparsity in the hidden units. Also, It has been shown that the deep neural networks can be trained efficiently compared than sigmoid and logistic regression activation function.

**III) ReLULAYER :**

Rectified Linear Unit(ReLU) layer is an activation function.

$$f(x) = \max(0, x)$$

x – input to the neuron; also a ramp function

A smooth approximation to the rectifier is the analytic function

$$f(x) = \ln(1 + e^x)$$

**iv) DROPOUT LAYER**

The crucial part of the deep convolutional neural network is handling the parameters generated from each stacked layers abundantly. It may cause over-fitting. For avoiding such scenarios, dropping out some neurons in the layer which cascaded to the next layer. Usage of dropout mainly near Fully connected layer to avoid excessive generation of parameters. It is a widely used regularization techniques.

The feed forward operation of the dropout layer network[9] can be described as (for  $n \in \{0,1,\dots,N-1\}$  and any hidden unit i)

$$r_j(n) \sim \text{Bernoulli}(p)$$

$$y_d(n) = r(n) * y(n)$$

$$z_i(n+1) = w_i(n+1) y_d(n) + b_i(n+1) ; y_i(n+1) = f(z_i(n+1));$$

Also, it cause some drawbacks of missing out the information from previous layers to the next layers. It shown those effects on model learning the parameters through back propagation error analysis.

**v)FULLY CONNECTED LAYER**

The layer which comes after the cascaded convolutional and max/average pooling layer is called Fully connected layer. The high level reasoning is done through this layer during classification. A fully connected layer takes all neurons in the previous layer from max-pooling layer and connects it to every neuron it has. Fully connected layers are not spatially connected anymore. It visualize as one-dimensional layer.

**vi)CLASSIFICATION LAYER :**

After the stacked or deep multiple layers, the final layer is a softmax layer which stacked at the end for classifying the fundus image followed by the fully connected layer output. Here, the deciding as a single-class classification or multi-class classification.

**V. ANALYSIS OF RESULT**

The performance evaluation of any neural network is done on the basis of some specific parameters which decides whether the current model is justified for the dataset or not.

Evaluation Metrics: The measurement of an accuracy for the network architecture is estimated by correctly classified DR suffered images from the pool of images in the different dataset. Also, evaluate the algorithm which will be suffered by over-fitting or under-fitting could be visualized by plotting the training and validation loss. A whole objective is to minimizing the cost function of the

deep convolutional neural network result s significantly reflected in the testing datasets.

In terms of diabetic retinopathy performance measurements, Specificity (SP), Sensitivity (SE) and Accuracy (Acc) are the crucial parameters for deciding the algorithms. Four parameters which take part in measuring those performances are:

The measurement of an accuracy for the network architecture is estimated by correctly classified DR suffered images from the pool of images in the different dataset. Also evaluate the algorithm which will be suffered by over-fitting or under-fitting could be visualized by plotting the training and validation loss. A whole objective is to minimizing the cost function of the deep convolutional neural network results significantly reflected in the testing datasets. In terms of diabetic retinopathy performance measurements, Specificity(SP), Sensitivity(SE) and Accuracy(Acc) are the crucial parameters for deciding the algorithms. Four parameters which take part in measuring those performances are :

True Positive(TP)- Correctly detected DR images

True Negative(TN) - Correctly detected Non-DR images

False Positive(FP) - Number of Non-DR images are detected wrongly as DR images

False Negative(FN) - Number of DR images are detected wrongly as Non-DR images

At last, the Sensitivity, Specificity and Accuracy are measured for each fundus images available in the database.

$$SE = \frac{TP}{TP + FN} \quad SP = \frac{TN}{TN + FP}$$

$$Acc = \frac{TP + TN}{TP + TN + FP + FN} \quad Precision = \frac{TP}{TP + FP}$$

Sensitivity (true positive rate or recall) measures how likely the test is positive who someone have a diabetic retinopathy. Specificity (true negative rate) measures how likely the test is someone don't have the diabetic retinopathy. Positive predictive value is also called as Precision. Accuracy measures the diabetic and non-diabetic patients from the database

$$Accuracy = \frac{TN + TP}{TN + FP + FN + TP}$$

$$Precision = \frac{TP}{TN + TP}$$

**Dataset :**

Kaggle dataset[19] : A high-resolution retina images taken under a variety of imaging conditions. A clinician rated the presense of diabetic retinopathy and scale it as 0-4. It contain 35126 training images and 53576 test images.

DRIVE dataset[20] : This database contain 40 color eye fundus images taken with Canon CR5 3CCD camera with 45 degree field of view. It separated as train and test images by two experts.

STARE[21] : This dataset contain 20 color eye fundus images taken with the TopCon TRV camera with 35 degree field of view. Each image has a resolution of 700\*605.

## VI. RESULTS

### Pre-processing :

Input images is scaled down to 256x256. Fig.5.1, shows the database input images and its resized monochrome images.

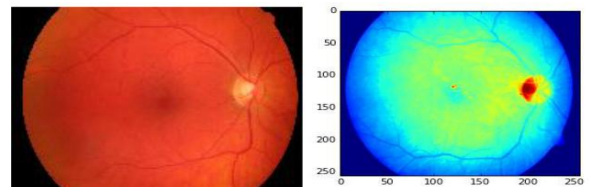


Fig 5.1 Input image  
5.2 Monochrome image

In Table 5.2 Confusion matrix results is shown the classification reports of the trained datasets.

Table 5.2 Confusion matrix results

		Predicted Results				
		Class-0	Class-1	Class-2	Class-3	Class-4
Actual	Results	25712	48	29	17	4
		382	2051	7	2	1
		962	112	4197	20	7
		136	0	16	736	13
		42	0	2	17	647

The performance evaluation reports are obtained as shown in the table 5.3.

Table 5.3 Performance evaluation reports

Stages	Precision	Recall(SE)
Class-0	0.99	1.00
Class-1	0.83	0.66

Class-2	0.79	0.68
Class-3	0.84	0.72
Class-4	0.91	0.77

An overall accuracy has achieved around 94% for classifying the diabetic retinopathy stages with the STARE and DRIVE dataset.

### VII. CONCLUSION

Among other existing supervising algorithms, most of them are requiring more pre-processing or post-processing stages for identifying the different stages of the diabetic retinopathy. Also, other algorithms mandatorily requiring manual feature extraction stages to classify the fundus images. In our proposed solution, Deep convolutional Neural Network(DCNN) is a wholesome approach to all level of diabetic retinopathy stages. No manual feature extraction stages are needed. Our network architecture with dropout techniques yielded significant classification accuracy. True positive rate(or recall) are also improved. This architecture has some setbacks are: An additional stage augmentation are needed for the images taken from different camera with different field of view. Also, our network architecture is complex and computation-intensive requiring high-level graphics processing unit to process the high resolution images when the level of layers stacked more.

### FUTURE WORKS

Among other existing supervising algorithms, most of them are requiring more pre-processing or post-processing stages for identifying the different stages of the diabetic retinopathy. Also, other algorithms mandatorily requiring manual feature extraction stages to classify the fundus images. In our proposed solution, Deep convolutional Neural Network is a wholesome approach to all level of diabetic retinopathy stages. No manual feature extraction stages are needed. Our network architecture with dropout techniques yielded significant classification accuracy. This architecture has some setbacks such as an additional stage augmentation are needed for the images taken from a different camera with a different field of view. Also, our network architecture is complex and computation-intensive requiring high-level graphics processing unit to process the high-resolution images when the level of layers stacked more. We can also implement our whole model as an application on mobile phones, so as to make

diabetic retinopathy detection easier and time-saving.

### REFERENCES

- [1]. S.Wang, et al, "Hierarchical retinal blood vessel segmentation based on feature and ensemble learning", *Neurocomputing*(2014), <http://dx.doi.org/10.1016/j.neucom.2014.07.059>.
- [2]. MrinalHaloi, "Improved Microaneurysm detection using Deep Neural Networks", *Cornel University Library*(2015), arXiv:1505.04424.
- [3]. M.Melinscak.P.Prentasic, S.Loncaric, "Retinal Vessel Segmentation using Deep Neural Networks", *VISAPP*(1),(2015):577-582
- [4]. G.Gardner,D.Keating, T.H.Willamson, A.T.Elliott, "Automatic detection of diabetic retinopathy using an artificial neural network: a screening Tool", *British Journal of Ophthalmology*,(1996);80:940-944
- [5]. S.Roychowdhury, D.D.Koozekanani, KeshabK.Parhi, "DREAM: Diabetic Retinopathy Analysis Using Machine Learning", *IEEE Journal of BioMedical and Health Informatics*, Vol.18, No 5, September (2014).
- [6]. J.Lachure, A.V.Deorankar, S.Lachure, S.Gupta, R.Jadhav, "Diabetic Retinopathy using Morphological operations and Machine Learning", *IEEE International Advance Computing Conference(IACC)*, (2015).
- [7]. R.Priya, P.Aruna, "SVM and Neural Network based Diagnosis of Diabetic Retinopathy", *International Journal of computer Applications*(00975-8887), volume 41-No.1,(March 2012).
- [8]. S.Giraddi, J Pujari, S.Seeri, "Identifying Abnormalities in the Retinal Images using SVM Classifiers", *International Journal of Computer Applications*(0975-8887), Volume 111 – No.6,(2015).
- [9]. N.Srivastava, G.Hinton, A.Krizhevsky, I Sutskever, RSalakhutdinov, "Dropout: A simple way to prevent Neural networks from overfitting", *Journal of Machine learning research*(2014) 1929-1958
- [10]. G.Lim, M.L.Lee, W.hsu, "Transformed Representations for Convolutional Neural Networks in Diabetic Retinopathy Screening", *Modern Artificial Intelligence for Health Analytic Papers from the AAI*(2014).
- [11]. P Kulkarni, J Zepeda, F Jurie, P Perez, L Chevallier, "Hybrid Multi-layer Deep CNN/Aggregator feature for Image



- Classification”, Computer Vision and pattern recognition, ICASSP conference, (2015).
- [12]. E M Shahin, T E Taha, W Al-Nuaimy, S.ElRaaie, O F Zahran, F E Abd El-Samie, “Automated Detection of Diabetic Retinopathy in Blurred Digital Fundus Images”, IEEE International Computer Engineering Conference , pages-20-25,(2012).
- [13]. Xiang chen et al, “A novel method for automatic hard exudates detection in color retinal images”, Proceedings of the 2012 International Conference on Machine Learning and Cybernetics, Xian (2012).
- [14]. VesnaZeljкови et al, “Classification Algorithm of RetinalImages of Diabetic patients Based on Exudates Detection”, 978-1-4673-2362-8/12, IEEE(2012).
- [15]. Michael Nielsen,” neural network and deep learning.com/chap6.html”
- [16]. Kaggle  
dataset:<https://www.kaggle.com/c/diabetic-retinopathy-detection/data>
- [17]. DRIVE dataset[online] :J.J. Staal, M.D. Abramoff, M. Niemeijer, M.A. Viergever, B. van Ginneken, "Ridge based vessel segmentation in color images of the retina", IEEE Transactions on Medical Imaging, 2004, vol. 23, pp. 501-509.
- [18]. STARE dataset[online] :  
<http://www.ces.clemson.edu/~ahoover/Stare>.

Yenni Manaswini, et. al. “Detection of Diabetic Retinopathy using deep Convolutional Neural Network.” *International Journal of Engineering Research and Applications (IJERA)*, vol.10 (11), 2020, pp 39-47.